

## Introduction

Cataract surgeons world over have accepted the basic fact that post cataract rehabilitation of patients dependent on how soon a person can resume his /her routine activities which is hampered by too much variation of his post operative refraction. Reduction in size of incision has played a big role in bringing about faster stability of wound healing and refraction of patients. Smallest possible incision of course is desirable, and is truly being practiced during phacosurgery with advent of foldable IOL. Phacoemulsification, a modern technique is improving every day to make itself a safe technique in all hands. Unfortunately, lack of training facilities, cost and maintenance problem of machine has made this procedure limited to big cities/institutions only. Non-phaco small incision is not as small as phaco incision in clear cornea but is of intermediate size say upto 5.5 to 6.5 mm. At the same time induced astigmatism has to be kept at minimum for which location and configuration of incisions is modified to compensate for the larger size required in non-phaco small incision cataract surgery (SICS).

The concept of scleral pocket incision developed by Richard Kratz was a beginning in this direction. It has been shown by Thrasher and Buerner that 9mm posterior (scleral) incision induces less astigmatism than 6mm limbal incision. Jaffe has stated that 7mm incision 2mm behind the limbus can be left unsutured without fear of induced against the rule astigmatism. We shall leave the subject of induced astigmatism at this point and deal with it in detail in other section.

Alternate small incision cataract surgery techniques are also being practiced by many eminent surgeons of the world. Anterior chamber maintainer assisted mini-nuc technique of professor M. Blumenthal and other techniques practiced by surgeons like W. R. Bryant, Luther L. Fry, Peter Kansas etc. are keeping alive the interest in manual small incision cataract surgery.

In our own country centres like Aravind Eye Hospital, Madurai and many individual surgeons are practicing the “ Small incision cataract surgery (SICS)” with excellent results. There’s immense demand for small, practical “how to do” manual of SICS. This communication is an attempt to fill that need.

**Dr. Ruchi Goel**

**Dr. K.P.S. Malik**

## Preoperative Preparation and Anaesthesia

**Dr. Amit Goel** D.A., M.S.

A medical clearance is obtained. Wide spectrum antibiotic drops topically every four hours a day before surgery is instilled. Mydriasis is achieved using cyclopentolate 1% or tropicamide 1% along with phenylephrine 5-10% drops. Topical 0.03% flurbiprofen or diclofenac sodium 0.1% every 20 minutes thrice will maintain intraoperative mydriasis.

Peribulbar / retrobulbar / subconjunctival / subtenon / topical / intracameral preservative free xylocaine with or without facial block can be used.

Our preferred technique is –

1. Topical Xylocaine 4%/ Proparacaine 0.5% 4-5 times
2. 3 cc xylocaine 2 % + 3cc bupivacaine .75% as an inferior temporal peribulbar injection. 3 cc is injected peribulbar, needle is withdrawn, directed lateral to lateral canthus, deep enough to inject the solution around the branches of facial nerve. This one prick anaesthesia should take care of every need of SICS.

No use is made of mannitol, diamox, massage, pressure or superpinky. The need is for normotensive eyeball. Some movements of eyeball are acceptable and would not interfere with smooth execution of the procedure.

### ANAESTHESIA

#### **Peribulbar**

Less painful

No seventh nerve block required

Minimal complications

Longer duration of postoperative analgesia

#### **Retrobulbar**

Painful especially upon penetrating the muscle sheath.

Seventh nerve block required

Potentially devastating complications

Shorter duration of post operative analgesia

## TOPICAL ANAESTHESIA

This is gaining widespread popularity due to high rate of patient satisfaction, minimal discomfort & safety but should not be tried by a beginner. An experienced surgeon and a cooperative patient is a prerequisite for this type of anaesthesia.

Besides avoiding complications associated with injectable anaesthesia, there is rapid visual recovery, with minimal postoperative ecchymosis and edema.

4% lidocaine in drops, one drop every 5 minutes four times prior to operation & additional drop whenever necessary is instilled in conjunctival sac. 1ml of 2% lidocaine subtenon anaesthesia can be used at site of scleral incision and additional 1% lidocaine 0.5ml is injected intracamerally.

## COMPLICATIONS

These are mainly seen in cases of retrobulbar block.

1. Hypotension, bradycardia, cardiac arrest, diaphoresis and nausea are usually in response to fear or pain of injection or manipulation of eyeball.
2. **Oculocardiac Reflex** :Known as Achner's reflex first described in 1908. A variety of stimuli arising in or near the eye may cause abnormalities of the rate or rhythm of heart. It is suggested that patients with blue or grey eyes are less likely to develop oculocardiac reflex dysrhythmia than similar patients with brown or hazel eyes. Cardiac standstill is a danger preceded by bradycardia especially following traction on medial rectus or pressure on eyeball. Therefore cardiac monitoring is a must. Gallamine and Atropine are useful preventives. Glycopyrronium has similar effect but causes less tachycardia. Hyoscine bromide also has been recommended.
3. Retrobulbar haemorrhage. Treatment consists of gentle pressure for 20-30 minutes and rescheduling of surgery after one week.
4. Scleral perforation.
5. Optic nerve damage and direct spread of LA to CNS along the optic nerve sheath resulting in brain stem anaesthesia and life threatening complications.

## Drugs

A molecule of local analgesic drug possesses an aromatic or lipophilic group and a hydrophilic group with a linking chain which may be an ester (COO) or an amide (NHCO).

**Lignocaine hydrochloride (xylocaine, lidocaine)** It is amide linked and one of the most commonly used local analgesic agent. It is stable, not decomposed by boiling, acids or alkalis. 4% solution for topical analgesia & 1.5-2% with 1:1,00,000 adrenaline is used for nerve block.

It has a cerebral effect, causes drowsiness and is excreted renally.

Duration of effect of 1% solution is 1hr., which prolongs to 1.5 to 2 hrs. with Adrenaline. Maximum safe dose in 70kg man with adrenaline is 500mg, i.e. 7mg/kg and without adrenaline 200mg, 3mg/kg. Toxic effects of lignocaine are twitching, convulsions, apnoea and acute cardiac failure.

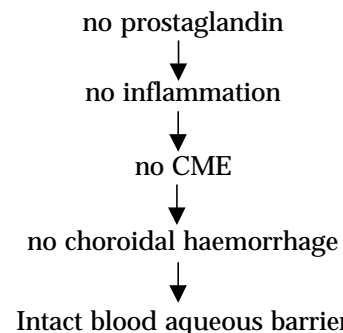
## Bupivacaine

Amide type local analgesic synthesized in Sweden by Ekenstam in 1957. Four times as potent as lignocaine. Bupivacaine is more cardiotoxic than lignocaine, which is made worse by hypoxia, hypercapnia and pregnancy. It causes more sensory than motor block. It is longest acting local anaesthetic agent. Maximal dose is 2mg/kg (25-30ml of 0.5% solution). With adrenaline its effect is not prolonged but toxicity is reduced.

## WHY NOT HYPOTONY ?

Concept of hypotony was introduced for safe ECCE where in surgeons made 13-15 mm corneoscleral incision. Iris prolapse or lens extrusions were common bugbears in absence of hypotony. Physiologically a normotensive eyeball is the best proposition as vascular dynamics of retinal and uveal tissue are minimally disturbed in normotensive state . The following flow chart indicates the advantages of maintaining a normotensive eyeball .

Maintenance of vascular dynamics of eyeball



In small incision cataract surgery as practised by Dr. Blumenthal, 'AC maintainer system' keeps the AC deep and IOP at normal or higher level. This pressurized state of eye is required for easy hydro expression of nucleus from the eyeball.

**Hypertonic state of the eye ball also facilitates the following :**

1. Introduction of MVR 20G/V-Lance knife for sideport entry or for AC maintainer
2. Dissection of sclerocorneal tunnel
3. Even for curvilinear capsulorhexis the deep AC and pressure on anterior capsule is necessary to counter the intra lenticular pressure.

Hydroexpression of epinucleus, cortex or blood.

## Sclero corneal pocket Tunnel

The experience of eminent surgeons like Prof. M. Blumenthal of Israel and others practicing the art of non-phaco small incision cataract surgery has refined the incision to its present form with optimum results. The incision recommended today is sclero corneal pocket tunnel type.

### Merits of Sclero-corneal pocket tunnel incision

1. Minimal induced astigmatism.
2. Faster healing and stabilization
3. Less tendency for against the rule shift (ATR)
4. Patient is more comfortable as incision area is covered by conjunctiva.
5. Even if suture is given, it is covered completely by tenon and conjunctiva producing no irritation.

### Demerits

1. Technically difficult to master
2. Maneuverability of the instruments is hampered by the long tunnel

### Techniques of making sclero-corneal pocket tunnel

The incision area is prepared by detaching the conjunctiva from limbus at 11 o' clock to 2 o' clock position. The conjunctiva is undermined, attachment of tenon is severed. All episcleral tissue should not be removed as it initiates the healing. Light and minimal cautery is applied on perforating vessels or large surface vessels. Excess cautery can lead to shrinkage of tissue and is best avoided.

### Incision

The incisions are created in variety of ways. It is obligatory to understand the limbal anatomy prior to discussing the design of the incision.

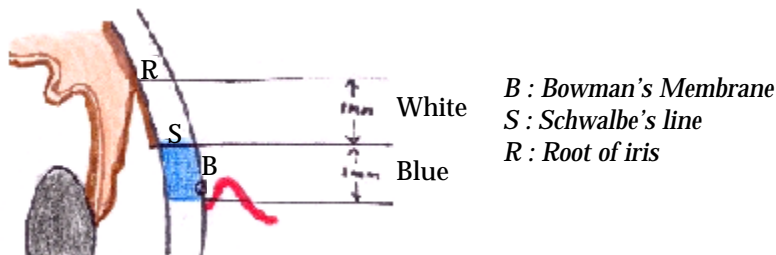


Fig. 2.1: Surgical anatomy of Limbus

## LIMBAL ANATOMY

Anterior border of limbus is located at the posterior edge of conjunctival attachment on the cornea coinciding with the end of Bowman's membrane. Posterior to it is 1mm bluish zone overlying clear cornea. Posteriorly it blends with whitish area, blue white junction overlying schwalbe's line i.e. the end of Descemet's membrane. The whitish zone too is about 1mm wide overlying the trabecular meshwork.

Incision making consists of three parts as detailed:

- I. Making the scleral groove (external incision)
- II. Dissecting the sclero-corneal pocket tunnel.
- III. Entry into anterior chamber (internal incision).

### I. Making the scleral groove (external incision)

The external incision can be of different shapes. Some are easier to make, others are not so. Following shapes of external incisions are used in SICS. We shall discuss their characteristics and infer how to choose one of them.

- A. Straight : Scratch incision is made at 12'O clock position 1.5mm away and parallel to the limbus, 5.5-6.5 mm in length.


The straight incision is likely to induce more ATR astigmatism. This type of external incision is easy to make and is best practiced by beginners. (Fig. 2.2)

- B. Frown shaped : A parabolic groove convex towards limbus is made 1.5-2mm behind limbus centered at 12'O Clock. (Fig.2.3)

- C. Inverted "V" -Incision line AB, BC is created, point B being just short of limbus at 12'O clock (point A and C shall lie 2 to 2.5mm behind limbus. AB and BC lines will make an angle of 120-130°. (Fig.2.4)


Frown and inverted "V" are the external incisions which have their ends running radially away from the limbus which will prevent the sliding down of wound thus preventing the ATR shift of astigmatism, in contrast to a straight incision which may slide down if left unsutured and induce ATR astigmatism. Type B and C incisions are technically difficult to make, difficult to manipulate especially in small hypermetropic eyes with shallow AC. Beginner can gain experience of tunnel making by practicing straight tunnel incision first and then shift to more difficult, but rewarding frown shaped or inverted V incisions.

## Types of incisions



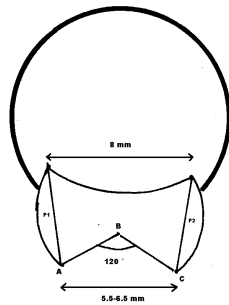
Straight

Fig. 2.2



Frown

Fig. 2.3



Inverted "V"

Fig. 2.4

## Instruments and Techniques

A guarded 0.3mm diamond knife is the best for making the groove. Alternately a 15° angled keratome or B.P. knife with 11 number blade can be used. Depth of external incision should be controlled and uniform. The blade should remain perpendicular to sclera. Remember, external incision is the gateway for adequate and efficient pocket tunnel dissection. A smooth, well defined, sharply cut, uniform scleral groove is therefore desirable.

## Pitfalls :

Too deep a groove, say upto supraciliary space will have following disadvantages.

1. Corneal tunnel dissection will be difficult or impossible. There are chances of premature entry into the anterior chamber.
2. Scleral disinsertion :Gerry Spindel reviewed several cases of scleral pocket incision which developed large amounts of ATR astigmatism. It was noticed that all of these patients had initially very deep scleral groove. A very deep scleral groove can cause scleral disinsertion ie. the complete separation of inferior sclera from the sclera superior to the incision. Since there is no support for the sclera from the groove to the limbus - incision closure inferior to the incision either by suture or by corneal valve will not be able to provide support to the sclera, hence the large gaping. This would necessitate the use of radial sutures for closure of incision.

Too shallow a groove - can result in button holing of sclera or cornea. Remedy lies in remaking the groove and dissection in another plane.

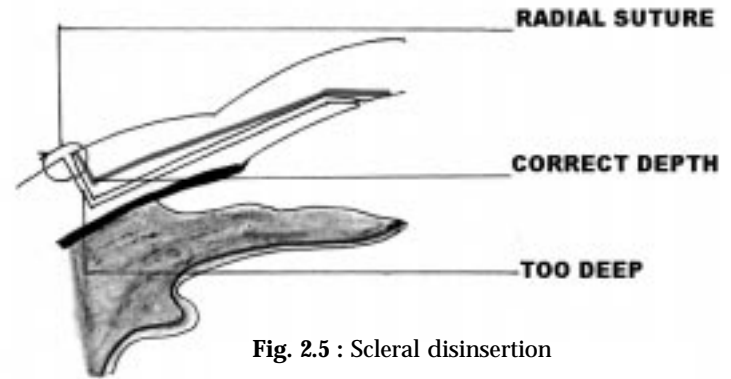


Fig. 2.5 : Scleral disinsertion

## Dissection of sclero-corneal pocket tunnel.

Geometry of sclerocorneal pocket tunnel has been envisaged to have a smaller external incision, a large internal incision and large side pocket dissection. This configuration of outlet, allows the largest of the nuclei to be accommodated and manipulated out of AC, at the same time, corneal valve advantage assures the quick closure of AC to the outside environment. Corneal valve closure also ensures least amount of induced astigmatism.

## Techniques

The instrument used to dissect the tunnel is 2.8mm angled crescent with bevel up. The groove is engaged by crescent edge and forward movement is made. As soon as one reaches the limbus blade is lifted up and anteriorly along the dome of the cornea to dissect it uniformly. 1.5 to 2.00 mm of clear cornea is dissected. Once a straight tract has been created, the crescent is moved side ways to right and left, keeping in dissected plane. Conscious effort is made to tilt the knife keeping the curved contour of the cornea in mind to prevent shallowing of tunnel laterally and preventing any button holing of the cornea. Side pockets in sclera and cornea are dissected by turning the blade 60-70° away from 12 o' clock meridian.

At the end of the dissection picture will be as in the Figure 2.3.

Note that side pockets P1 and P2 are extra spaces created to accommodate the bulk of the nucleus during its

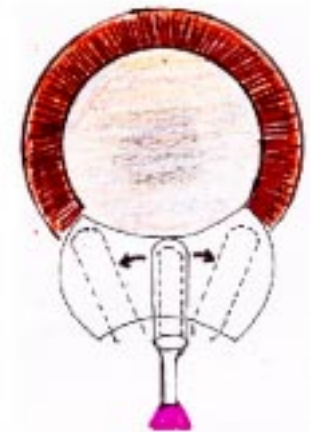

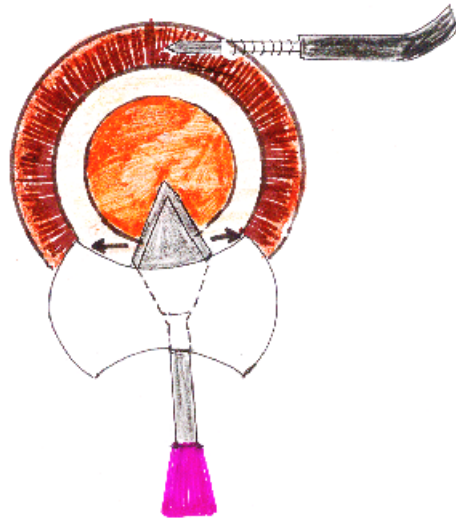
Fig. 2.6: Dissecting the corneoscleral tunnel by angled 2.8mm crescent knife

journey out of the A.C. It is also to be observed that planned internal incision at the anterior end of the tunnel would be larger than external incision.

### **Entry into the Anterior Chamber**

#### ***(Making the internal incision)***

Although described here, this is made after capsular opening and fixing the AC maintainer. 2.8mm or 3.2 mm angled keratome is the suitable instrument for the creation of internal incision. AC being maintained deep either by ACM flow or by viscoelastic, the angled keratome is introduced into the pre-dissected sclero-corneal pocket tunnel. With side to side movement the tip of keratome will reach the extreme anterior limit of the tunnel. A correctly dissected tunnel will reveal, that end of keratome is about 2mm in clear cornea. The bevel of keratome is lifted to dip the tip into AC, with forward movements, the keratome held parallel to iris – multiple entries are affected one after other in quick succession. The quickness of movement is important for maintaining the depth of anterior chamber. Keratome is next turned 80° or 90° side ways to accomplish the lateral ends of internal incision. Pocket areas (P1 and P2) can be revisited while withdrawing to make sure that the dimension of pocket areas is as desired.



**Fig. 2.7:** Completing the corneo-scleral tunnel by 3.2mm angled keratome

#### **Pitfalls and remedies:**

Commonest mistake made during making of internal incision is premature entry into the AC. This entry may be near to the root of the iris – which will then obstruct and prolapse out during further maneuvers. Identification of anterior extreme of tunnel is facilitated by red colouring of tunnel by blood elements released during dissection or else viscoelastic may be injected to clearly define the tunnel area in cornea and then to proceed with angled keratome for AC entry. We recommend forward movement of keratome while cutting in and not to cut while pulling out. This ensures the uniform cut in Descemet's membrane and the internal incision will be in one line parallel to the limbus.

***Never hold the lips of external incision for fixing the eyeball.***

***You will damage the tunnel!***

## Capsular Opening

After the tunnel has been dissected with crescent knife, entry is made into the anterior chamber at 10 O' Clock position with MVR/V-Lance 20G blade. Viscoelastic is injected to make the eyeball hypertensive (30-35 mm of Hg). Three types of capsular openings can be made to ensure the IOL placement in the bag. It is to be noticed that with can opener type of capsulotomy, the bag placement of IOL may not always be possible.

1. Continuous circular capsulorhexis
2. Envelope
3. Can-op-rhexis

### Capsulorhexis

In 1984, Gimbel for the first time in North America presented continuous tear capsulotomy with almost simultaneous development by Neuhann in West Germany in 1985, who called it circular capsulorhexis. The Asian surgeon Shimuzu called it circular capsulotomy in 1986.

The technique can be performed by a variety of methods and all give the same results.

### Advantages of Capsulorhexis

#### Intraoperative

1. The edges can be distorted during operation and the capsule can be stretched considerably.
2. The continuous circular aperture limits the risk of tears or radial crack's which tend to extend towards the equator and towards the posterior capsule during the operation.
3. Hydrodissection is safe
4. The intraoperative stress on the zonules is minimal and is distributed evenly at the equator.
5. Easier cortical aspiration.
6. IOL can be positioned safely & symmetrically in the bag.
7. IOL can be placed on the rhexis in cases of PC rupture.

#### Postoperative

1. Allows uniform distribution of forces within the capsular bag and prevents the IOL from displacements and effects of mechanical pressure.
2. Produces an extensive contact area between the haptics of the IOL and the anterior capsule which reduces the possibility of decentering.

3. Ensures that there is no contact with the ciliary body. The possibility of iris contact, pigment dispersion, hyphaema, and inflammation is reduced.

### MECHANICS OF CAPSULORHEXIS

A planar material can be torn either by 'stretching' or 'shearing' once the tear is initiated. The difference lies in the magnitude and direction of force.

#### TEARING BY STRETCHING

The plane of application of the force is in the plane of the material which is also the plane of the maximum strength of the material. A force sufficient to overcome the maximum strength of capsule in a direction perpendicular to the desired direction of the tear is applied. The free flap is pulled towards the centre to prevent it from moving out of control towards the equator.

Since the force required should be sufficient to overcome the maximum resistance of the capsule, this type of tearing once started, will progress rapidly, and can easily go out of control.

The capsule can tear in an undesired direction with less force than is needed to make it tear in the desired direction, using this method.

#### TEARING BY SHEARING

Here the effective angle of the applied force at the tearing vertex is perpendicular to the plane of the material. The applied force is in the direction of the least resistance of the planar material (Perpendicular to its plane), so only minimal force is needed to tear it. There is lesser chance of extending to the equator than if stretching is used.

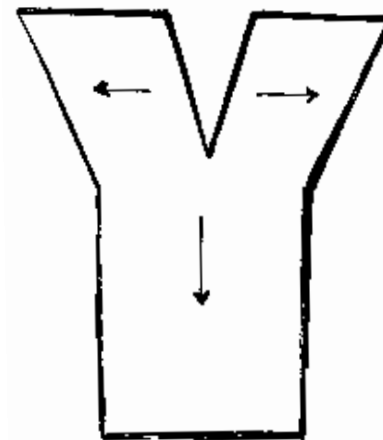


Fig.3.1 : Tearing by stretching

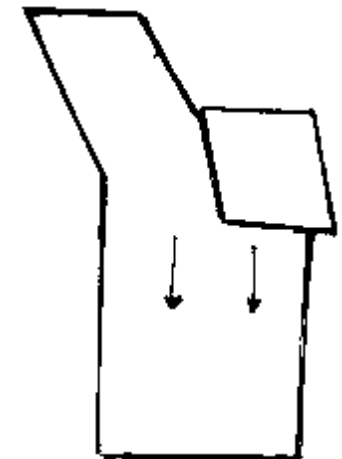
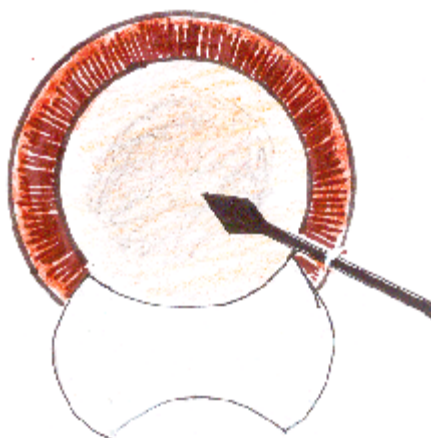
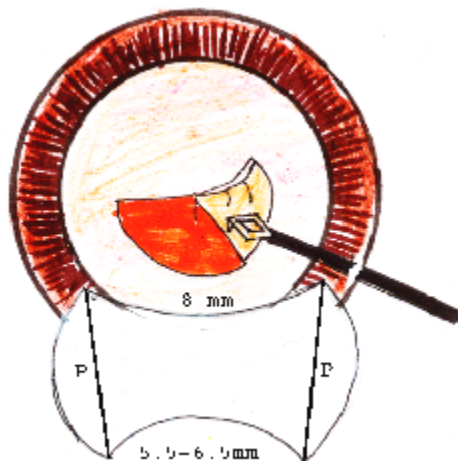


Fig. 3.2: Tearing by shearing



**Fig. 3.3 :** Side port entry for performing CCC



**Fig. 3.4:** Making curvilinear capsulorhexis

#### TECHNIQUE WITH CYSTOTOME AND VISCOELASTIC

We use 26G needle for making the cystotome. The first bent is at 90° close to the needle tip & the second bent at an obtuse angle.

The cystotome with a very sharp cutting tip is brought to rest at the centre of the capsule and a small medial opening is made. The cystotome is inserted just below the capsule, raising it. To form a small capsular flap. The cystotome is then placed above the flap and the flap is directed clockwise or anti-clockwise (our way) in relation to the desired diameter of the rhexis which should be at least 6mm in this technique. The cystotome is repositioned at least five to six times above the flap, near the end of the previous sector. Positioning the cystotome above the flap, care should be taken not to perforate the flap itself or the underlying anterior capsule, or to disturb the underlying cortex. Care should be taken to keep the AC deep all the time. Final tear is from outside to inside.

#### DIFFICULTIES DURING RHEXIS

##### Rhexis escape

If this occurs at any step, then one must ensure that the chamber is adequately deep. If not, inject viscoelastics.

#### TECHNIQUES OF RECOVERING AN ESCAPING RHEXIS

- After deepening the chamber, attempt should be made to direct the flap towards the centre of the pupil either with the cystotome or forceps.
- Alternative is to cut the capsule at the escape point using a curved

microscissors to redirect the opening back to the initial route.

- One can even start a new rhexis in another position working in a clockwise direction this time to join up with the first rhexis at the escape point.

#### PITFALLS & REMEDIES

1. If the rhexis size is too small it can be converted to can-op-rhexis.
2. It may be difficult to remove the cortex at 12 O'clock position beneath the rhexis. For this, after insertion of the IOL in the bag, radial cuts can be given at the desired direction for manipulation of the cannula. The dialing of the IOL itself will release the cortex at times.
3. If the capsular bag is grossly decentered, the IOL may become decentered in the post operative period because the capsular fibrosis shifts the lens towards the longest edge. It is advisable to remove the excess capsule during the operation.
4. Over ripe or intumescent cataracts: Lack of red pupillary reflex makes it difficult to perceive the capsular flap. In addition, the cataract is swollen, meaning that there is greater tension on the anterior capsule and a greater tendency to peripheral escape. Dyes to stain the anterior capsule should be used (dealt in detail later). With the intumescent cataract, if content is thought to be liquid or milk like, after performing a central incision, which will permit the escape of the semiliquid cortex, ACM should be put on to allow it to flow out. Rhexis can then be performed either with ACM on or after putting the ACM off, clean viscoelastics can be introduced. A 2 step CCC in which a small CCC is created followed by a second CCC to enlarge the initial opening can be performed.

#### COMPLICATIONS OF CAPSULORHEXIS

1. Shrinkage of anterior capsular opening resulting in capsular contraction syndrome.
2. Capsular bag distension.
3. Epithelial cell hyperproliferation on the posterior capsule.

#### CAPSULAR CONTRACTION SYNDROME

It is relatively frequent with capsulorhexis but rarely seen with can opener with anterior radial capsular tears.

The syndrome consists of an exaggerated reduction in the anterior capsulotomy opening and equatorial capsular bag diameter. This may lead to malposition of the capsulotomy opening and displacement of the IOL & is more in smaller capsular openings and older patients.

The capsular bag contraction occurs secondary to fibrous dysplasia

of residual lens epithelial cells, associated with relatively unopposed weak zonular support. It is common in pseudoexfoliation, advanced age, uveitis & myotonic muscular dystrophy.

Capsular fibrosis is caused by metaplastic lens epithelium. In a large capsulotomy, lesser epithelium is left thereby decreasing the potential for capsular contraction.

The other factor is the sphincter effect of an intact capsulorrhexis. Early anterior radial Yag laser relaxing capsulotomy helps to resolve the ultimate contraction of the anterior capsulotomy opening.

### CAPSULAR BAG DISTENSION

'Capsular block' implies fluid hyperdistension of the capsular bag due to occlusion of the circular anterior capsule opening by the IOL optic. Source of fluid is unclear, it may be retained viscoelastic, transudation through the lens capsule or exudation from the lens epithelial cells.

It is generally self-limiting. A small Nd: Yag laser opening in the anterior or posterior capsule permanently relieves the capsular block.

### HYPERPROLIFERATION OF LENS EPITHELIAL CELLS

This occurs in the form of Elschnig's pearls on the central posterior capsule & is also known to surround a previously made laser capsulotomy.

### ANTERIOR CAPSULAR STAINING IN ADVANCED CATARACTS

It is difficult to perform a CCC in absence of red reflex. With poor visibility, errant capsule tearing is common and difficult to control, jeopardizing in the bag IOL implantation. The accepted recommendations are:

- Dimming the room light
- Increasing the magnification of the operating microscope
- Coaxial illumination
- Use of high density viscoelastics
- Use of air
- Endoilluminator
- 2 stage CCC approach
- Dye to stain the anterior capsule

### CHARACTERISTIC OF THE 3 DYES FOR ANTERIOR CAPSULE STAINING

	Concentration	Advantages	Disadvantages
Fluorescein sodium	0.2%	Blue light enhancement	Low molecular weight; vitreous leakage;
Indocyanine green	0.5%	can be used High molecular weight; no vitreous leakage	corneal staining Cost may be prohibitive
Trypan blue	0.1%	High molecular weight; no vitreous leakage; commercially available at reasonable cost	

### TECHNIQUES OF STAINING

1. Staining under an air bubble
2. Intracameral subcapsular injection
3. Intracameral supracapsular injection

### STAINING UNDER AN AIR BUBBLE

Air is injected using side port entry. 0.1ml of dye is injected over the anterior capsular within the air bubble. After a few seconds, dye is washed & viscoelastic are injected in the anterior chamber. We have been directly injecting the dye into the AC without cover of air and have observed no ill-effects on the endothelium so far.




Fig. 3.5: Dye injected over the anterior capsule

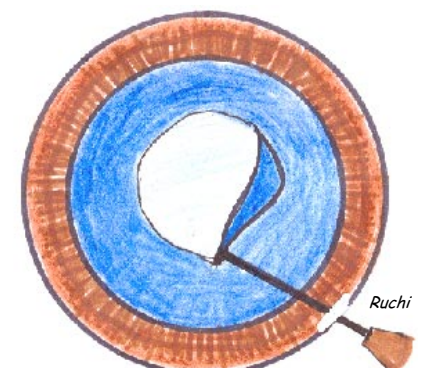


Fig. 3.6: Anterior capsule stained with trypan blue and CCC being performed



## CHARACTERISTICS OF THE 2 TECHNIQUES FOR ANTERIOR CAPSULE STAINING : STAINING UNDER AN AIR BUBBLE

<i>Advantages</i>	<i>Disadvantages</i>
Technically less invasive	Air filled anterior chamber is unsteady.
Staining of peripheral anterior capsular rim, providing good visibility.	Progressive dilution of the dye by aqueous.

### INTRACAMERAL SUBCAPSULAR INJECTION

After the aqueous is replaced with viscoelastics, 0.05 to 0.1 ml of the dye is injected beneath the anterior capsule with a 30 G needle. A slight leakage of dye from the subcapsular space is observed during this step. After the stained viscoelastic is replaced by clear one, the point of injection can be used for beginning the CCC.

<i>Advantages</i>	<i>Disadvantages</i>
<ul style="list-style-type: none"> <li>● Dye remains trapped in the subcapsular space.</li> <li>● Good staining of the posterior surface of the capsular flap</li> <li>● Injection hole can be used for initiating CCC</li> </ul>	<ul style="list-style-type: none"> <li>● Technically more invasive</li> <li>● Tear of the anterior capsule with excessive injection of dye.</li> </ul>

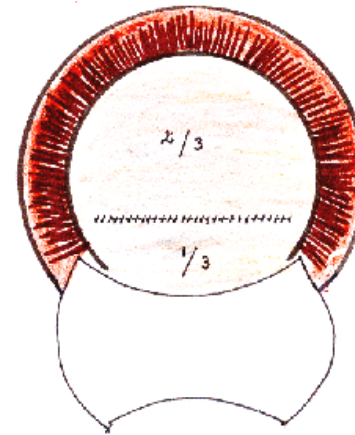
We are routinely using Trypan blue dye which is commercially available in India.

### INTRACAMERAL SUPRACAPSULAR INJECTION

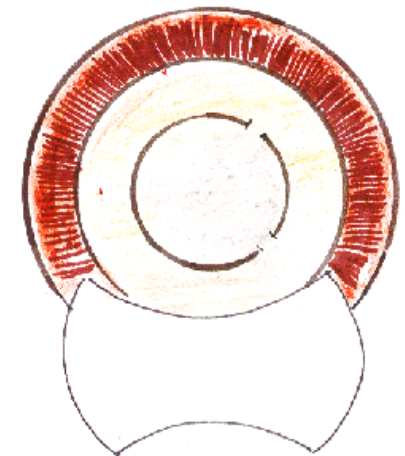
We are now routinely using this technique with no ill effects on the endothelium. After making the sideport entry, dye is injected directly into the AC till whole of aqueous is stained. The dye is then washed after 5 to 10 seconds using copious amounts of BSS or Ringer lactate. Sufficient amount of capsular staining is obtained by this method.

### ENVELOPE TECHNIQUE

Envelope technique is preferred over canopener in cases where CCC is difficult. In case of morgagnian, intumescent black/brown or hypermature cataract envelope making is an easy and excellent technique which allows all the benefits of CCC.



**Fig. 3.7:** Envelope capsulotomy



**Fig. 3.8:** Relaxing cuts in the rhexis (can-op-rhexis)

A scratch mark is made at the junction of lower 2/3<sup>rd</sup> and upper 1/3<sup>rd</sup> of capsule. Further tiny cuts are given medially and laterally saving 1 mm of capsule on either side, cuts are then joined by a horizontal line. This type of capsular opening is useful for placement of IOL in the bag. After placing the IOL in the bag the remnants of anterior capsule are cut off by cystotome or Vanas scissors

### CAN-OP RHEXIS

A CCC may be given relaxing cut at 7 & 11-12 'o clock position for nuclear manipulation out of the rigid CCC margin in cases of hard or large nuclei. Can-op rhexis opening will give all the benefits of CCC and allow in the bag placement of IOL. Therefore, while performing CCC if one loses control and part of it has to be completed by can opener technique, it is still preferable to have some round margin of capsular opening.

### FIXING THE AC MAINTAINER

Fix the AC maintainer at this stage as AC is still deep with viscoelastic. MVR entry is made at 6 'o clock parallel to limbus, away from the vascular arcade of cornea. The AC maintainer, a hollow steel tube with 0.9 mm outer and 0.65 mm inner diameter is entered with bevel up and then turned 180 degrees so that the bevel faces the iris. The AC maintainer is always inserted from the temporal side. The tube of AC maintainer is attached to BSS bottle suspended 60-70 cm above the patient's eye.

## PITFALLS AND REMEDIES

1. AC maintainer may not enter the opening made for the purpose. The reason may be a) Too narrow a opening made with a knife of caliber less than 20G. Remedy lies in enlarging the opening to the required size because if it is too large then the ACM may keep slipping out or chamber may keep on leaking. b) While inserting the steel tube it has to be held from the steel portion and not too far away, holding it too far away may result in difficulty in its insertion.
2. Injury to iris or Descemet's membrane while inserting the tube. Care has to be exercised to keep the direction of tube while entering in AC.
3. **Stromal oedema may occur if part of the bevel remains in the stroma. Corneal haziness makes further surgical maneuvers difficult therefore one has to ensure that the bevel is completely in AC facing the iris.**

## CHAPTER 4

# Hydro Procedures

It is imperative to understand the surgical anatomy of the lens prior to performing hydroprocedures.

### SURGICAL ANATOMY OF THE LENS

The lens is a biconvex body. In a young adult the diameter of the lens is 9-10 mm and its thickness is 4-4.5 mm. The junction of the two peripherally located convex surfaces constitutes the lens equator. The antero-posterior thickness of lens in intumescent cataract may be as much as 7 mm and in hypermature cataract it may diminish to 2.5 to 3 mm. The lens is completely surrounded by a collagenous elastic capsule secreted at the embryonic stage as a basement membrane by the lens epithelium. Capsule is composed of two layers, the outer zonular lamellae into which the zonular fibres insert, and the inner lamella. The capsule is thicker anteriorly than posteriorly.

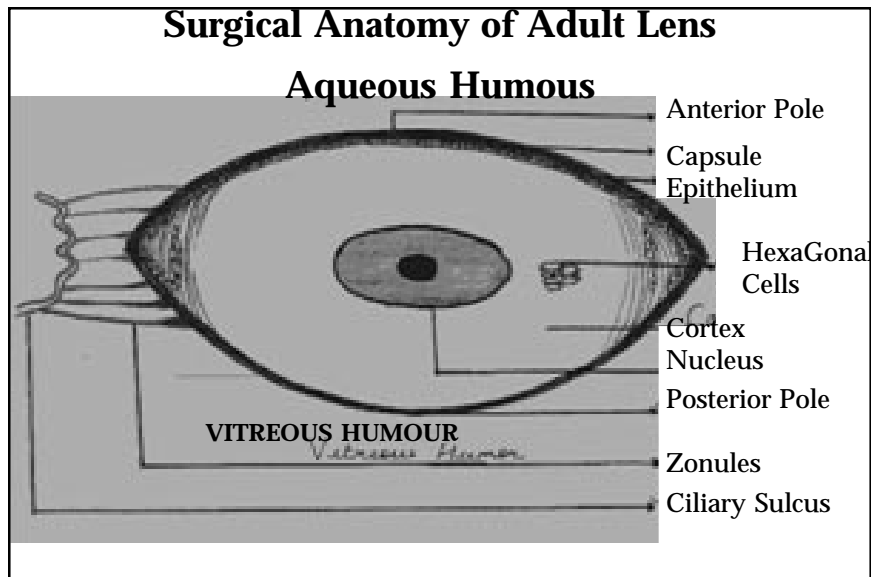
Beneath this capsule anteriorly there is a mono-layer of cuboidal nucleated epithelial cells in which almost all the metabolic, synthetic and transport processes of the lens occur. These cells divide, elongate and differentiate equatorially to produce long, thin, regularly arranged fibres. As the new cortical fibres grow concentrically, the central, older fibres become more densely packed and form the lens nucleus.

### HYDROPROCEDURES

Hydroprocedures comprise of hydrodissection and hydrodelineation. The aim is to separate the lens nucleus, epinucleus and cortex from capsule and the lens lamella from the cortex and its different layers. This facilitates rotation of nucleus from its bag into the anterior chamber. In addition to simplifying all the surgical maneuvers on the nucleus itself, it also prevents all the pressure exerted on the nucleus from being transferred to the capsule and zonular apparatus. Therefore thorough hydroprocedures play a key role in this surgery. Hydroprocedures were first described by Michael Blumenthal but the term hydrodissection was given by Faust. These procedures can be carried out with anterior chamber maintainer in on or off state.

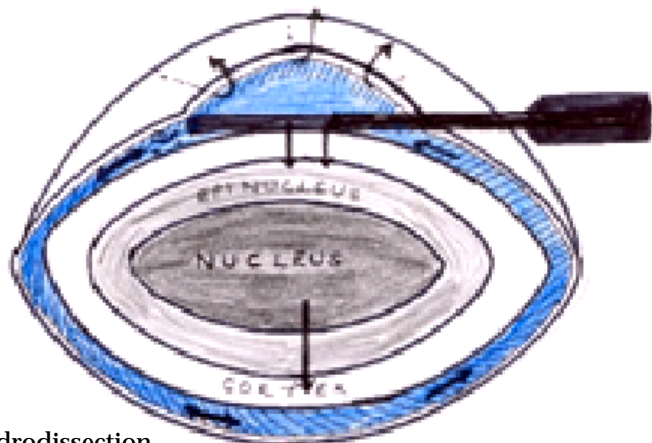
### HYDRODISSECTION

AC is emptied of viscoelastics remaining after capsulorhexis. 1 CC ringer lactate/BSS is loaded onto 2 cc syringe and is injected behind the rhexis margin using a suitably angled cannula with a blunt tip (like Healon cannula) in different directions. The bolus of fluid injected between ante-



**Fig. 4.1:** Surgical anatomy of adult lens

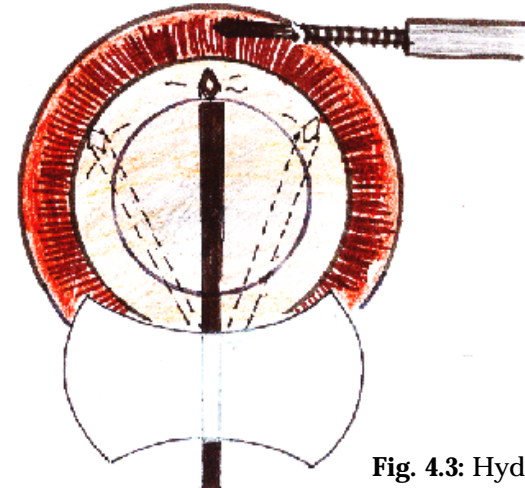
rior capsule and cortex dissects all around the capsular bag and separates it from the nucleus. The cortex is completely dissected from the capsule freeing the entire lens nucleus, epinucleus, cortex from the capsular bag thereby facilitating nuclear rotation and manipulation out of its bag. Indication that the dissection has occurred is shallowing of anterior chamber, signifying entrapment of fluid in the subcapsular layer of the lens at one pole. Intermittent gentle tapping releases the fluid collected behind the nucleus thereby completing the hydrodissection.



**Fig. 4.2:** Hydrodissection

### Pitfalls and Remedies

Hydrodissection should be carefully performed if rhexis margin is not intact because of risk of extending the tear to the posterior capsule. Take care to decompress the capsular bag with every injection of fluid. Decompress by exerting pressure on the central part of nucleus with a cannula in order to express the liquid trapped between the nucleus and the posterior capsule. An excessive quantity of BSS with inadequate decompression can rupture posterior capsule or even rupture the rhexis.



**Fig. 4.3:** Hydrodissection

Insufficient hydrodissection is the most common complication which makes subsequent manipulation of nucleus difficult and provokes excessive traction on the zonules and the capsule.

### HYDRODELINEATION / HYDRODELAMINATION / HYDRODEMARCATIION

The fluid is injected between the epinucleus and nucleus. The fluid wave appears as a golden ring under the surgical microscope. The procedure is carried out using either a straight cannula or one with 2 sideports. The final result is a debulking of nucleus. The cannula is passed into the nucleus until it meets resistance where the soft outer nucleus ends and a firm inner nucleus begins. At the point of resistance the cannula is pulled back a fraction of a mm and fluid is injected. The fluid passes into the body of the cataract and creates a cleavage plane. This may be repeated at a different site. In a very hard cataract, the inner nucleus may extend right out to the capsule and cleavage plane may never be identified whereas in a soft cataract multiple planes may be isolated. Thorough hydroprocedures reduce the size of the nucleus which in turn enable the surgeon to deliver it out of a small incision.

## Nucleus Management

Nucleus management consists of two important and delicate maneuvers.

1. One is getting the nucleus out of capsular bag.
2. Second is delivery of nucleus out of the anterior chamber without injury to corneal endothelium.

### Getting the nucleus out of capsular bag

Through hydroprocedure ensures freeing of nucleus from capsular bag. If the CCC size is adequate, the nucleus will pop out of the bag without much doing. We recommend that rhexis size should be >6mm or else give relaxing cuts to rhexis margin at 7 and 12'O clock position. We have also learnt by experience that if rhexis is created in a such a way that capsular rim near 12'O clock incision is narrow, one gets greater freedom to approach the upper pole for hydrodissection – which also makes freeing of upper pole easy. Another important benefit of this narrow capsular rim is easy approach of the upper pole of nucleus either by Sinskey hook or a hydro canula. We wish to re-emphasize the importance of really effective hydrodissection. We also recommend the following procedure to be adopted for confirming the freedom of nucleus in the capsular bag. After hydrodissection and hydrodelineation – take two sinskey hooks, one in each hand and introduce them, one through side port and one through the main incision. Proceed gently to the surface of hard part of the nucleus under safety of deep anterior chamber and rotate the nucleus bimanually. During the procedure one hook fixes the nucleus and other rotates it clock wise or anti clock wise. Rotation of nucleus means the nucleus is completely free of bag and can be maneuvered out of it. In case of hypermature cataracts as the fibers are mostly degenerated, liquified nucleus will rotate without much effort. Whereas in cases of im-

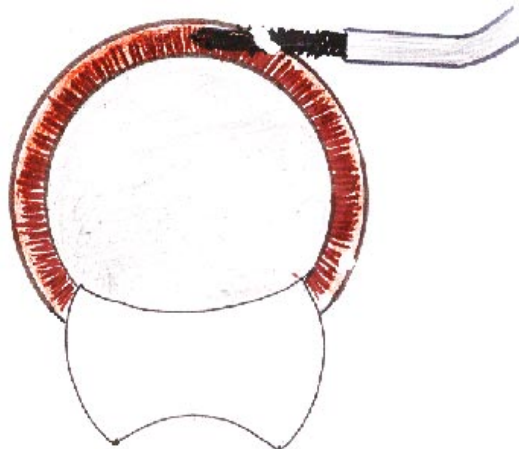


Fig. 5.1: Nucleus in AC

tend to be firmly adhered to each other in cortical area and also with the capsular bag especially in equatorial area. One can resort to another go at hydroprocedures if nucleus seem to unyielding to 'Rotation test'.

### Pitfalls

An attempt at bimanual rotation of nucleus without adequate hydroprocedures may dislocate whole nuclear bag or cause partial dehiscence of zonules. This will be reflected by eccentric dip of nucleus to one side. In such situation it is better to fill up the AC with visco, convert the capsulorhexis to can opener, enlarge the incision and proceed to deliver the nucleus as in ECCE after bringing the nucleus out of the bag.

**Remember to maintain AC deep all the time while dealing with nucleus. ACM is closed off and chamber is deepened with viscoelastic whenever dealing with nucleus in anterior chamber.**

After gaining the experience of few dozen cases one can manage the nucleus without viscoelastics in AC, chamber being kept deep by continuous flow from ACM, more so in cases of hypermature cataracts where nucleus is virtually free from capsular bag.

"Rotation test" ensures that the nucleus is ready to be moved out of the bag. AC is deepened with viscoelastic, sinskey hook is passed from main incision behind the upper pole of the nucleus between 10-12 O'clock position, nucleus is engaged and pulled upwards towards 12'O clock. Upper pole thus out of bag, viscoelastic is injected behind and in front of nucleus. Sinskey hook is again used to cartwheel nucleus out of the bag clock wise or anticlock wise, akin to a tube pulled out of tyre. Whole nucleus once out of the bag rests in front of the iris in AC now.

### Pitfalls and Remedies

If rhexis is small especially in area of 9-12O' clock, the large nucleus may drag the whole bag while it is being maneuvered out. Dehiscence of zonules may be seen from 9-11 O' clock area and prevention is by giving the relaxing cut in rhexis margin. Remedy after zonular dehiscence is to enlarge the rhexis by multiple relaxing cuts, and also to increase the incision and proceed like a ECCE procedure.

The envelope type of capsulotomy sometimes creates a peculiar problem. Nucleus is found free on rotation test, upper pole is out of bag but nucleus does not prolapse into the AC. Reason, some times difficult to appreciate is that large part of nucleus still remains behind the lower flap of anterior capsule. The nucleus keeps on rotating without giving a clue as to why it is not coming out of the bag. Remedies are

1. Pull the nucleus towards 12'O clock and inject visco elastic to deepen AC at 6'O clock. The lower flap of capsule may slide down leaving the nucleus.

2. If still unsuccessful then wash out the free cortex, deepen the AC with viscoelastic and give relaxing incision on lower flap of anterior capsule. Proceed to dial out the nucleus.

### GETTING NUCLEUS OUT OF AC

Free nucleus in deep AC is ready now to be propelled out of AC by hydropressure generated by ACM. The principle of technique is to

- A. Engage the nucleus into sclerocorneal pocket tunnel with the help of lens glide or thin iris repositor.
- B. Push the nucleus out by hydropressure.

For engaging the nucleus into the sclerocorneal pocket tunnel a lens glide is passed behind the nucleus 1/3<sup>rd</sup> or half nucleus width distance in a viscoelastic filled deep AC. The ACM is opened and slight pressure is applied on lens glide on scleral side. Intermittent pressure will engage more and more nucleus bulk into the tunnel. Built up hydropressure will push the nucleus out of tunnel mouth. Subsequently, few more intermittent taps will enable the epinucleus and cortex to flow out of the AC. Lens glide is then pulled out.

If lens glide is not available then a thin iris repositor can perform the function of lens glide.

### Assisted delivery of nucleus

Nucleus shows a bit out of section but further progress is stalled, with full ACM on and lens glide in place. In such a situation, the help of 23G needle as an additional tool can be taken to assist the delivery of nucleus. We proceed to deliver the nucleus by engaging the nucleus at right angle to its axis with 23G needle. While the ACM generated hydropressure pushes

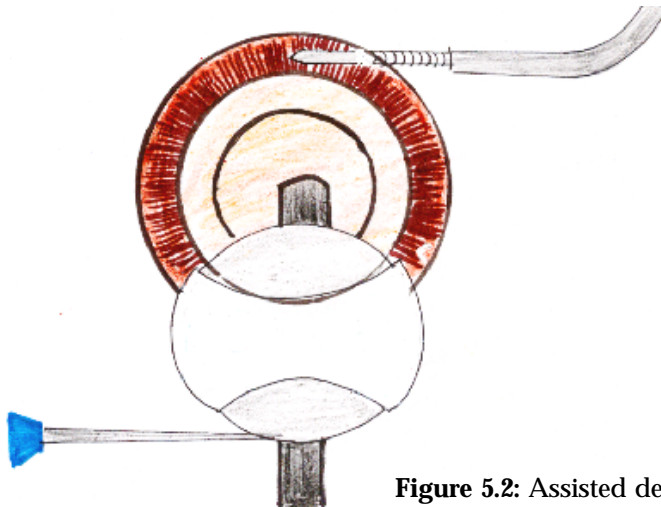


Figure 5.2: Assisted delivery

the nucleus out, the needle assists by pulling it out. At times needle can repeatedly engage the nucleus on more and more of extruded portion of nucleus to cart wheel it out safely. In case the nucleus is very large and hard, a bit of it may be sheared off, pushed back into the AC and smaller diameter may be allowed to flow out.

### Pitfalls and Remedies

If nucleus is not engaging into the inner lip of tunnel despite the full volume of AC flow, reasons may -

1. Tunnel is small
2. Tunnel is irregular.
3. Some fibres in tunnel are still adhering
4. AC is leaking through side port or irregularly created main opening.
5. Premature entry in AC with the iris obstructing the outlet.

Remedy is to stop the ACM, deepen the AC with viscoelastic, re-visit the tunnel with 3.2mm angled keratome making sure no resistance is encountered in whole of tunnel. Enlarge side ways if so warranted, deepen the corneoscleral pockets if not done already.

Don't struggle in shallow AC. Corneal endothelium the unforgiving tissue is nearby - respect it.

Adequate size of corneoscleral pocket tunnel and sufficient hydropressure should achieve the objective of delivery of nucleus. Pressure in AC can be raised by raising the fluid bottle height.

If iris shows out everytime the ACM is on, reason is insufficient tunneling of cornea and entry into AC near the root of iris. In such a situation nucleus can be delivered only through a larger incision. It should be done at the earliest and repeated attempts should be avoided to prevent damage to iris and cornea.

In hard, brown nucleus which would not yield to any hydropressure it is better to have a larger external incision.

For enlarging the incision, ACM is closed off and AC is deepened with viscoelastics 3.2 mm angled keratome is engaged in pre-dissected plane and moved cutting sideways to the right and left while maintaining the 3-planar section.

### Cortex washout

Most cortex can be washed out with ACM on and intermittent opening of external incision. Remaining cortex can be washed out by irrigation and aspiration Simcoe canula.

## Postoperative Astigmatism Following SICS

Advanced techniques of cataract surgery are transforming simple rehabilitative surgery into increasingly precise refractive surgery. Today the goal is to achieve emmetropia.

Induced corneal astigmatism is governed by interaction of wound compression and wound gape. Factors affecting the wound compression and gape are: -

1. Nature of incision -
  - A) Site
  - B) Configuration
  - C) Size
2. Scleral cauterization
3. Use of topical corticosteroids
4. Suturing

### NATURE OF INCISION

Corneal incision causes greatest, limbal intermediate while scleral incision cause least astigmatism. This has been supported by Lundsgaurds (1925), Welsh (1969), Jaffe NS (1971), Gills (1974) and Patrick JR (1978).

Rosen (1999) described the rationale of clear corneal incisions as: -

- Excellent access to lens
- Bloodless incision
- Quick & easy to perform
- Self sealing / sutureless
- Small incisions, <3mm will not induce astigmatism.

There has been increasing popularity of temporal incisions. Theories for ATR shift in the superior location of a corneal unsutured tunnel incision were first described by Fine et al (1993).

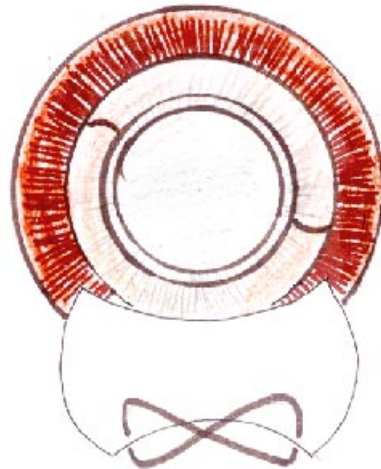
They gave the following reasons: -

1. Movement of the upper lid has a massaging effect on wound lips.
2. Temporal, vertical incisions re-epithelize quicker than superior, horizontal incisions.
3. Because of ellipsoidal shape of the cornea, the temporal clear corneal incision is located further from the center of the cornea than the superior clear cornea incision.

Maurizio Zanini (1997) also observed that temporal clear corneal incisions appear to induce more predictable, stable and lower astigmatism than superior scleral incisions because of corneal wound healing and the incision's distance from the optic axis.



**Figure 5.3:** Passing the figure of 8 suture



**Figure 5.4:** IOL in the bag, section closed

### Placing the IOL in bag

ACM is removed, capsular bag and AC is filled with viscoelastic. IOL is held with strong armed, flat tipped IOL holding forceps. The lower haptic and optic are guided into the bag and trailing haptic is dialled in using Sinskey's hook or 'y' shaped dialer.

### Suture or no Suture

Most sclero corneal-pocket tunnel incisions are self sealing. An adequate airpressure or fluid pressure in AC will tightly shut off the valvular opening. The side port and ACM port can be hydrated with proper cannula. Section can be checked for leak by applying slight pressure on the globe and accordingly suture can be applied if required.


### Suturing

∞ Infinity shaped suture covering most of the external incision is sufficient. The first bite is taken from the inner lip of sclera to exit at outer lip on left side of incision, suture is crossed over to cornea on right extreme of incision. Next bite is taken from outer lip of cornea to the section to exit at the sclera.

The suture is then crossed over again to left side to take the corneal bite and to finally tie the knot in the section thereby burying it in the section itself.

The scleral pocket technique was first described by Richard Kratz. It still remains one of the best ways to have a small, stable and secure incision. As described in the beginning we are using superior sclero corneal tunnel incision.

The external incision is of three types viz. Straight, frown and inverted 'v' shaped. The importance of external incision on astigmatism can be understood by the incisional funnel.



**Fig. 6.1:** Incisional funnel with various external incisions

The incisional funnel is bounded by a pair of curvilinear lines whose shape is based upon the relationship between astigmatism and two characteristics of incision : length and distance from the limbus. Incisions made within the funnel will be astigmatically stable. Short linear incisions made close to the limbus and longer incisions further away will have equivalent corneal stability.

A curvilinear incision made parallel to the limbus crosses out of the incisional funnel and is unstable. The straight incision placed at the same distance still falls outside the funnel, and is unstable. It is more stable than the curvilinear incision but not as stable as frown or 'v' shaped.

Frown and 'v' shaped lie entirely within this funnel. Moving the linear incision away from the limbus will make it stable but also hampers surgery by increasing the length of funnel.

Clear corneal tunnel incision gained widespread popularity but has its own demerits. According to Kurt Wizard, "it is by no means certain that shift of the external opening of the incision towards the cornea (from the sclera) is beneficial, and in fact it is our contention that it is a negative development with disadvantages that are hidden by the smaller size rou-

tinely used for clear corneal incision".

The disadvantages of clear corneal incision are :

- Difficulty in obtaining square incisional geometry (length of the tunnel must be equal to or exceed the width of the incision) since a long-tunnel through the cornea presents a problem during manipulation of anterior chamber. This phenomenon is called OARLOCKING.
- Since the tunnel in a clear corneal incision cannot be very long, square geometry dictates the external incision to be limited in length. In non-phaco SICS incision size cannot be less than 4mm.
- Corneal tissue does not heal quickly and is not usually subjected to fibrosis, and forms relatively weak adhesive bonds making the incision less secure.

We compared the postoperative astigmatism in 100 subjects between SICS using 6mm superior straight sclerocorneal pocket tunnel incision closed with one infinity suture (group I) and phacoemulsification using unsutured superior 4mm clear corneal incision (group II) by performing retinoscopy at 1 week, 4 weeks and 2 months postoperatively.

The mean astigmatism at 1 wk, 4 wk and 2 months in group I was  $1.77 \pm 0.533$ ,  $0.725 \pm 0.354$  and  $0.1 \pm 0.202$  respectively in group II was  $0.83 \pm 0.296$ ,  $0.265 \pm 0.217$  and  $0.04 \pm 0.105$  respectively. Significant decline ( $p=0.000$ ) occurred by 2 months in both the groups. Higher values were obtained in group I at 1 wk and 4 weeks but by 2 months there was no significant difference between the 2 groups ( $p=0.067$ ).

Ulrich Mester et al (1993) used fibrin glue for wound closure. They conducted a comparative study of 385 consecutive patients 167 received only fibrin glue for wound closure and 218 had single stitch. 5.5 – 6mm superior sclerocorneal pocket tunnel incision was used in all the patients. Astigmatism at 6 months was 1.12 D in the single stitch group and 0.89D in the fibrin group (U test,  $p<0.05$ ). Only 3.0% of fibrin group and 11.9% of the single stitch group had post-operative astigmatism greater than 1.75D. Astigmatic change was significantly smaller in fibrin group, as evaluated by vector analysis (0.84D compared with 0.99D; U-test  $p<0.05$ ).

We have no experience with fibrin glue so far.

## 2. Scleral cauterization

Troutman (1992) proposed that thermal energy leads to crosslinking of collagen leading to uneven shrinkage of wound and difficulties in even closure. Shrinkage of collagen leads to WTR astigmatism.

## 3. Use of Excessive corticosteroids

Stainer et al (1982) concluded that topical glucocorticosteroids retard wound healing and result in increased amount of ATR astigmatism.

## 4. Suturing

In 1999 we had studied the astigmatism between sutured and

unsutured scleral pocket tunnel incision in SICS and found that astigmatism was significantly higher in unsutured group at 1 wk ( $3.01 \pm 1.0D$ ) as compared to sutured group ( $1.68 \pm 0.648D$ ). But by 6 weeks no significant difference remained, the unsutured group had  $0.125 \pm 0.310 D$  and the sutured group had  $0.075 \pm 0.181 D$  of astigmatism.

We therefore conclude that frown shaped superior scleral incision whether sutured or unsutured results in minimal post-operative astigmatism and is suitable for non-phaco SICS.

## Steps of Sics in Short

1. Topical / peribulbar anaesthesia
2. Conjunctival flap, retracted
3. Sclera lightly cauterized
4. Frown, scratch incision 5.5 – 6.5mm, 1.5 to 2mm away from limbus.
5. Sclero corneal pocket tunnel dissection by 2.8mm angled crescent knife upto 2mm in cornea, inner dissection in cornea more than outer incision.
6. Rhexis / can-op-rhexis/ envelope capsulotomy through side ports (10' O clock by 20G MVR blade/V lance knife).
7. Fix ACM at 6'O clock parallel to limbus inside the vascular arcade.
8. Deepen AC with viscoelastic, and enter into AC through pre-dissected area by 3.2mm angled keratome.
9. Hydrodissection and hydrodelineation, bimanual rotation of nucleus under viscoelastic.
10. Nucleus out of the bag into AC, viscoelastic in front & behind the nucleus i.e. nucleus in ocean of viscoelastic
11. Lens glide or iris reposer behind the nucleus (open the ACM now), intermittent pressure on scleral side of incision. Nucleus is engaged pushed out by ACM created hydropressure. Delivery assisted by 23G needle and/or raising of bottle height.
12. Epinucleus & cortical wash by ACM flow
13. Pull out ACM now – clean the bag of remaining cortex by simcoe cannula
14. Fill capsular bag and AC with viscoelastic and place the IOL in bag
15. Hydrate the side port, ACM site and check the leakage of section.
16. Infinity suture if required.



## Suggested Readings

- Gills PJ. The effect of cataract surgery on postoperative astigmatism. AJO 1974; 97-100.
- Goel R, Malik KPS. To study the astigmatism between sutured and unsutured scleral pocket tunnel incision in SICS. Paper presented at annual conference of AIOS, Calcutta 2001.
- Jaffe N. Cataract surgery and its complications. CV Mosby Co., St. Louis, 6<sup>th</sup> ed, 1990.
- Maurizio Z, Georgio T, Piero B. Induced astigmatism and near clear hinge incision. J Cataract Refract Surg. Vol.23, 1997; 1190.
- Rosen E. Clear corneal incisions and astigmatism : In clear corneal lens surgery by Fine, Slack Incorporated, USA, 1999; pg.23.
- Rowan P. Corneal astigmatism following cataract surgery. Ann Ophthalmol 1978; 10 : 231-234.
- Rozakis GW. Cataract surgery – alternative small incision techniques. Jaypee Brothers, India.
- Stainer GA, Binder PS, Parker WT, Perl T. The natural and modified course of post-cataract astigmatism. OS 1982; 10 : 822-827.
- Troutman RC. Corneal astigmatism – Etiology, prevention and management. Mosby Year Book 1992; 1-10.
- Ulrich M, Markus Z, Martin R. Astigmatism after phacoemulsification with posterior chamber lens implantation; small incision technique with fibrin adhesive for wound closure. J Cataract Refract Surg, Vol.19, 1993; 616-619.

## Contents

### Introduction

1. Preoperative preparation & Anaesthesia
2. Corneo scleral tunnel
3. Capsular opening
4. Hydroprocedures
5. Nucleus delivery, IOL placement & Closure of section
6. Post operative astigmatism

### Steps of SICS in short

### Suggested readings

CME SERIES (No. 8)

---

*This CME Material has been supported by the funds of the AIOS, but the views expressed therein do not reflect the official opinion of the AIOS.*

---

# Manual Small Incision Cataract Surgery

(As part of the CME Programme)

**Dr. K.P.S. Malik** MS, MNAMS, FICS

**Dr. Ruchi Goel** MS

Department of Ophthalmology  
Safdarjung Hospital, New Delhi

*For any suggestion, please write to:*

**Dr. H.K. Tewari**  
Hony. General Secretary

*Published by:*

**ALL INDIA OPHTHALMOLOGICAL SOCIETY**

Dr. Rajendra Prasad Centre for Ophthalmic Sciences,  
All India Institute of Medical Sciences  
Ansari Nagar, New Delhi-110029

(ii)



**ALL INDIA OPHTHALMOLOGICAL SOCIETY**

 *Printed by :*  
*Syntho Pharmaceuticals Pvt. Ltd.*

(i)